K7
1916
$B 151 137

EXCHANGE

SIGILLVM · VNIVERSITATIS · CALIFORNIENSIS

LVX

FIAT

MDCCCLXVIII

EX LIBRIS

AUG 1 1917

TRANSIENT AURICULAR FIBRILLATION

An Electrocardiographic Study

Thesis presented to the Faculty of the Graduate School of the University of Pennsylvania in partial fulfilment of the requirements for the degree of Ph.D., 1916.

BY

EDWARD B. KRUMBHAAR, M.D.

(From the John Herr Musser Department of Research Medicine, University of Pennsylvania, Philadelphia.)



CHICAGO
AMERICAN MEDICAL ASSOCIATION
FIVE HUNDRED AND THIRTY-FIVE NORTH DEARBORN STREET
1916

Digitized by the Internet Archive
in 2007 with funding from
Microsoft Corporation

http://www.archive.org/details/transientauricul00krumrich

TRANSIENT AURICULAR FIBRILLATION

An Electrocardiographic Study

Thesis presented to the Faculty of the Graduate School of the University of Pennsylvania in partial fulfilment of the requirements for the degree of Ph.D., 1916.

BY

EDWARD B. KRUMBHAAR, M.D.

(From the John Herr Musser Department of Research Medicine, University of Pennsylvania, Philadelphia.)

Univ. of California

CHICAGO
AMERICAN MEDICAL ASSOCIATION
FIVE HUNDRED AND THIRTY-FIVE NORTH DEARBORN STREET
1916

TR C 682
K.7

BIOLOGY
LIBRARY

UNIV. OF CALIFORNIA

TRANSIENT AURICULAR FIBRILLATION

AN ELECTROCARDIOGRAPHIC STUDY*

EDWARD B. KRUMBHAAR, M.D.
PHILADELPHIA

In this communication are presented the results of a detailed study, by means of the electrocardiograph, of six individuals exhibiting the change from a normal heart rhythm to that of auricular fibrillation. Although the disturbance of cardiac mechanism that causes this type of cardiac irregularity—incoordinate contraction or fibrillation of the auricular musculature—has been understood only during the past few years, its clinical prototype, the pulsus irregularis perpetuus of Hering, or the totally irregular pulse, has for years been recognized as one of the commonest as well as one of the gravest forms of cardiac arrhythmia. Perhaps from the widespread use of Hering's terminology, however, the erroneous impression has been prevalent that this condition once present is practically always permanent. Already a sufficient number of cases have been published to combat this view, so that we must now consider that auricular fibrillation, like the other disturbances of the cardiac mechanism—premature contractions, heart block and alternation—may, though less frequently, occur in a transitory as well as a permanent form. My main thesis will be to show not only that transient auricular fibrillation constitutes a well recognized condition, but that it may be subdivided into three well-defined groups.

REVIEW OF THE LITERATURE

Cushny and Edmunds,[1] in the paper that first propounded the theory that a totally irregular pulse is due to fibrillation of the auricles, were led to their experimental work by the study of a woman who had had numerous paroxysmal attacks of fibrillation during several years of observation. No determining factor was discovered clinically, but the conclusion was reached that the attacks were due to reflex vagus inhibition.

---

*From the John Herr Musser Department of Research Medicine, University of Pennsylvania, Philadelphia.

1. Cushny, A. R., and Edmunds, C. W.: Paroxysmal Irregularity of the Heart and Auricular Fibrillation, Am. Jour. Med. Sc., 1907, cxxxiii, 66.

361268

Very similar cases have been reported by Fox,[2] Hornung,[3] G. C. Robinson,[4] Popper,[5] and Lewis and Schleiter.[6] These patients, as was Cushny and Edmund's patient, were all over 50 years of age and had had numerous attacks, lasting from a few minutes or hours to several days, and extending over many years. In none was a valvular defect present, but hypertension and preponderance of the left ventricles were found in all. Another interesting group of ten cases has been reported by Heitz,[7] together with polygraphic records, which unfortunately do not absolutely preclude the existence of some other form of arrhythmia. In another series, out of a total of 120 patients with auricular fibrillation examined electrocardiographically, Fahrenkamp[8] found only four in whom the trouble was transient (3.3 per cent.). Though paroxysmal in character, the attacks were all single and short (one fatal), seen in acute conditions, such as Graves' disease, pneumonia and septicemia. Further details of these cases will be considered later, in connection with the discussion of the cases here reported. The cases reported by Falconer and Dean[9] and by Schwarzmann[10] developed transient attacks of fibrillation in the presence of an already existing heart block. The complication that this causes makes it inadvisable to include them in this discussion.

The older theory that a temporarily but totally irregular pulse (delirium cordis) is not uncommon and frequently disappears under digitalis medication was in most cases due to imperfect observation. The probability is that in such cases the slight degree of arrhythmia, which became still less with the improvement of the patient, became unnoticeable to the touch, in spite of the fact that the underlying condition of fibrillation persisted. In some cases, also, as Fahrenkamp and others have pointed out, the occurrence of complicated groups of extrasystoles may (in the absence of electrocardiograms) present a picture indistinguishable from auricular fibrillation.

---

2. Fox, G. H.: Transitory Delirium Cordis, Am. Jour. Med. Sc., 1910, cxl, 815.
3. Hornung, O.: Ueber atypische tachykardische Paroxysmen, Deutsch. Arch. f. klin. Med., 1907, xci, 469.
4. Robinson, G. C.: Paroxysmal Auricular Fibrillation, The Archives Int. Med., 1914, xiii, 298.
5. Popper, H.: Ueber Anfälle von Vorhofflimmern, Med. Klin., 1915, xi, 885.
6. Lewis, T., and Schleiter, H. G.: The Relation of Regular Tachycardias of Auricular Origin to Auricular Fibrillation, Heart, 1911-1912, iii, 173.
7. Heitz, J.: La forme paroxystique de l'arythmie complete, Ann. de méd., 1914, i, 483.
8. Fahrenkamp, K.: Vorübergehende komplette Herzunregelmässigkeiten unter dem klinischen Bilde der Arythmia Perpetua mit Beobachtungen über Vaguswirkung, Deutsch. Arch. f. klin. Med., 1914, cxvii, 1.
9. Falconer, A. W., and Dean, G.: Observations on a Case of Heart Block Associated with Intermittent Attacks of Auricular Fibrillation, Heart, 1911-1912, iii, 247.
10. Schwarzmann, G. S.: Ueber ein Fall von Herz Block mit Paroxysmalem Vorhofflimmern, Zentralbl. f. inn. Med., 1914, xxxv, 1001.

The six cases of fibrillation mentioned above are here reported in detail, in the hope that they may throw some light on the poorly understood pathogenesis of this common and serious condition and on the prognosis of such transient cases. The fibrillation in four of the cases was found to be transient, and in the other two cases developed while the patients were under observation. These four represent 7.5 per cent. of the total number of cases of auricular fibrillation studied electrocardiographically at the University Hospital during a period of two

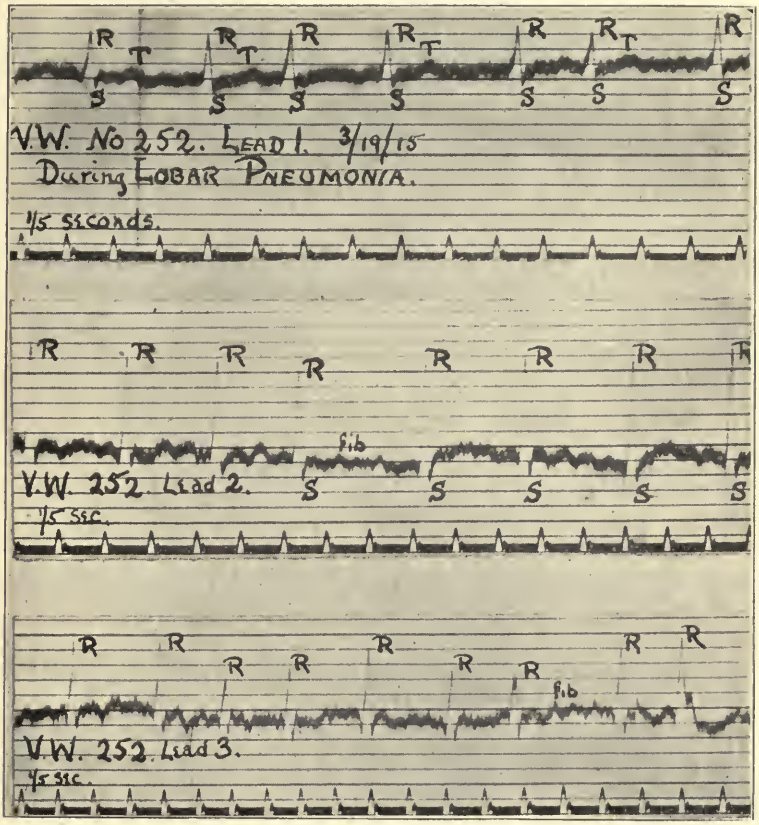

Fig. 1 (Case 1).—Electrocardiogram of V. W., showing transient auricular fibrillation in lobar pneumonia. In this, as in other electrocardiograms of this series, records were taken from the three customary leads. The tension of the string was so standardized that 1 millivolt caused a deflection of 1 cm. As the string could not be standardized with the patient in circuit, 1,400 ohms were added as an arbitrary equivalent of the patient's resistance. Platinum string, resistance about 3,500 ohms. Time intervals are expressed in fifths of second and occasionally by vertical lines indicating ⅕ and 1/25 second. In this figure, note (1) absence of sign of auricular contraction (P wave); (2) ventricular arrhythmia (irregular occurrence of R); and (3) occasional coarse waves of fibrillation.

and a half years. While this is apparently an unusually high percentage of transient fibrillation, it is very probable that the wider use of graphic methods of registration will in the near future demonstrate its greater frequency.

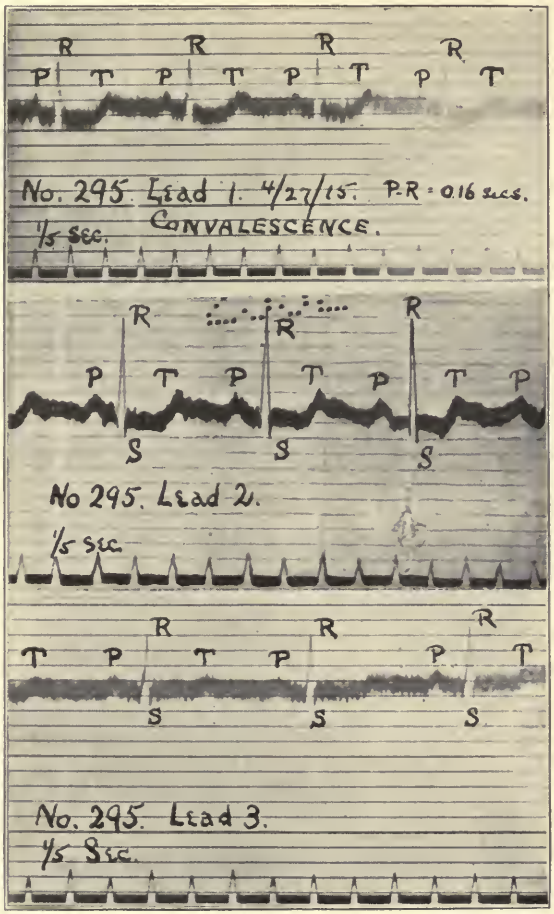

Fig. 2 (Case 1).—Electrocardiogram of same patient as in Figure 1, showing normal rhythm during convalescence from pneumonia. Note reappearance of P wave, regular occurrence of R and absence of fibrillation waves. (The print of Lead II, as in a few other instances, has been retouched for purposes of reproduction.)

I. TRANSIENT AURICULAR FIBRILLATION IN LOBAR PNEUMONIA

Case 1.—V. M., a white man, married, 53 years old, a tinsmith by trade, was admitted to the hospital March 17, 1915, on the third day of a typical attack of lobar pneumonia, involving the left lower lobe. A total arrhythmia was noticed on admission, although the patient had never noticed such arrhythmia before and had never to his knowledge had any previous cardiac trouble Cardiac dulness was not increased and there were no valvular murmurs. Except

for two attacks of gonorrhea twenty-five years before, he had never been seriously ill. He had never had rheumatism, tonsillitis or other fever, although a later blood examination gave a positive Wassermann reaction. The systolic blood pressure on admission was 120, diastolic 95. After the reestablishment of normal rhythm, the systolic pressure was 115, diastolic 85.

An electrocardiogram (Fig. 1) taken on the day of admission showed the presence of auricular fibrillation (of the coarse type), absence of the P wave and a moderate degree of arrhythmia. The form of the electrocardiogram shows no other deviation from the normal, except that the T wave is inverted in Lead III. Tincture of digitalis (0.6 c.c. three times a day) was begun at once and continued during the patient's stay in the hospital of more than a month. Although the pneumonic crisis was reached in four days after admission, with normal resolution of the involved lobe, the pulse rate remained over 100 for another ten days. The arrhythmia became less and less marked, until one month after admission, with the pulse rate varying between 60 and 90, arrhythmia was imperceptible. An electrocardiogram (Fig. 2) taken at this time showed a regular rhythm, with the reappearance of the P wave. The T wave in Lead III is no longer inverted and is more pronounced in the other two leads than in the former record. The patient was discharged in good condition and since then has had no return of any cardiac irregularity. A polygram (Fig. 3) taken three months later revealed a regular radial pulse (rate 62 beats per minute) with a normal jugular pulse. The fact that the myocardium had not yet returned to normal, however, was shown by the persistence of pretibial edema and dyspnea on exertion.



Fig. 3 (Case 1).—Normal polygram three months after pneumonia. Note regular radial rhythm and normal "a, c, v" type of venous pulse, with prominent "a" wave.

Summary of Case.—A patient in the third day of an attack of lobar pneumonia was found to have auricular fibrillation with considerable arrhythmia, although there had been no previous history of heart disease. After recovery from the pneumonia, the arrhythmia gradually decreased, until one month later the electrocardiogram showed a normal P wave and regular rhythm. The exact time at which the auricle began again to beat coordinately was not determined, but was apparently not accompanied by any noticeable subjective symptoms or change in rate. That the return to a normal rhythm was permanent is shown by polygraphic records taken three months later.

II. TRANSIENT AURICULAR FIBRILLATION OF NERVOUS ORIGIN IN SYPHILITIC MYOCARDITIS

Case 2.—B. A., a white woman, married, 38 years old, was admitted to the hospital March 2, 1915, for the removal of a uterine fibroid. She had had measles, mumps, appendicitis and typhoid, but had totally recovered from each, and had otherwise been healthy. Her husband was living and well, but she had had no children, one miscarriage, and the Wassermann reaction was strongly positive. She had never complained of any cardiac trouble until three

weeks before admission, at which time after a hard day's work she had an attack of palpitation, dyspnea and irregular heart action. Another attack occurred the next evening and the symptoms continued more or less marked until admission to the hospital. On the day of admission she had a similar

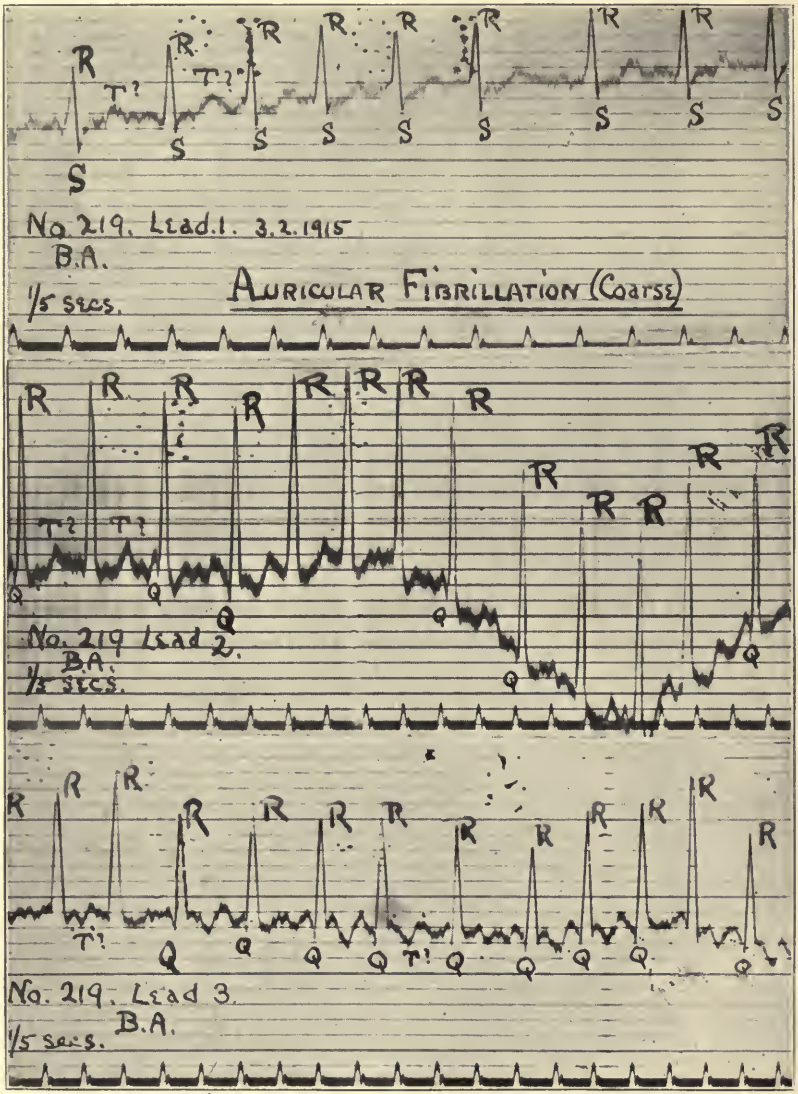

Fig. 4 (Case 2).—Electrocardiogram of Mrs. B. A., taken March 2, 1915, showing transient auricular fibrillation in syphilitic myocarditis. Note same disturbances of mechanism as in Figure 1.

attack, but more serious than any previous one, and the extreme rapidity and irregularity of the heart action necessitated the abandonment of the operation. The patient attributed this attack to the nervous excitement aroused by contemplation of the operation.

At the time of the electrocardiographic study she was in a very nervous state, with warm, flushed skin, and marked tremor of the hands. The radial pulse was distinctly irregular, rapid (180 per minute), quick, full, with increased tension, the wall slightly sclerotic. The cardiac dulness was slightly increased

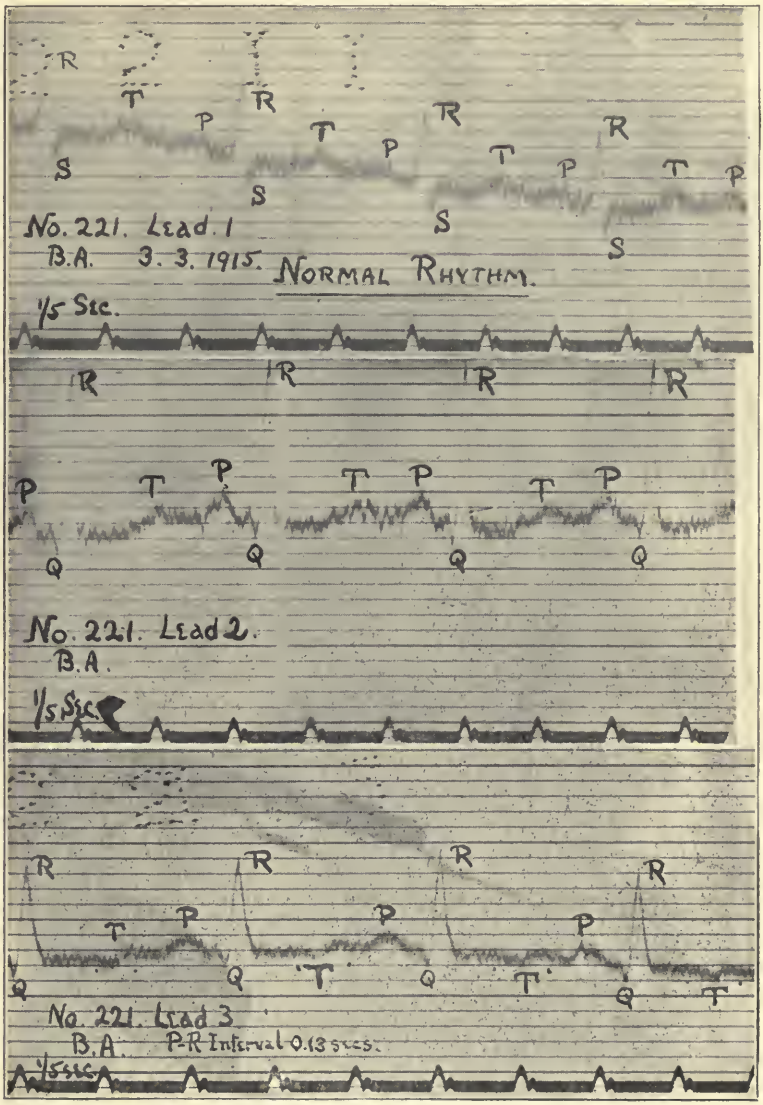

Fig. 5 (Case 2).—Electrocardiogram of same patient as in Figure 4, taken March 3, showing normal rhythm.

to the left, the apex beat distinct in fifth space, 12 cm. from the midline. There was a distinct apical systolic murmur transmitted to the axilla, with accentuated second aortic and pulmonic sounds. An electrocardiogram (Fig. 4) showed the arrhythmia to be due to an auricular fibrillation of the

coarse type. With the fear of operation removed, and after a quiet night in bed, the patient awoke the next morning without any disagreeable subjective sensations, and the pulse was regular and much slower. The systolic blood pressure, which during the attack of fibrillation had been 165, was found during the period of regular rhythm to be 132. The diastolic fell from 85 to 78.

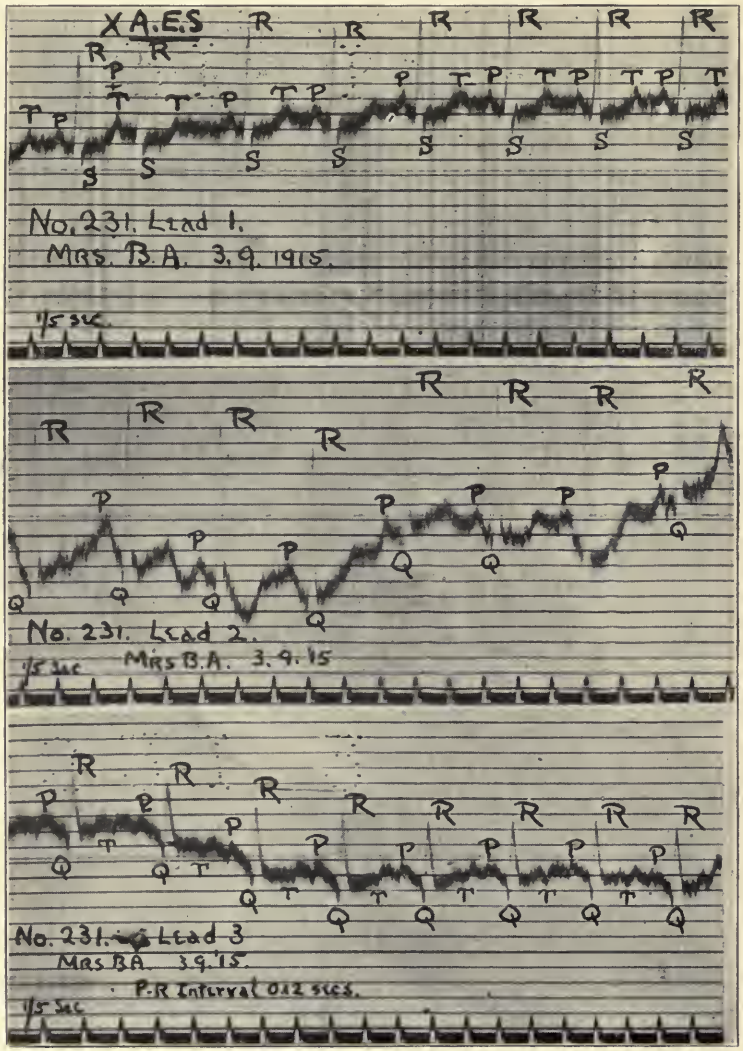

Fig. 6 (Case 2).—Electrocardiogram of same patient as in Figure 4, taken March 9, showing normal rhythm occasionally disturbed by an auricular premature contraction.

An electrocardiogram (Fig. 5) taken the same morning showed a regular rhythm, with a normal P wave. The complexes were practically the same as in the former record (the more rapid passage of the film being shown by the increased intervals of the time marker), except that systole (as indicated by

the end of T) lasted more than 0.3 second and was immediately followed by the next P wave. For several days the patient's improvement continued, the pulse being either quite regular or showing only an occasional slight irregularity. The nature of this irregularity is shown in Figure 6 to be due to an occasional extrasystole. Although there is practically a complete compensatory pause, this is probably an auricular extrasystole merging with the preceding T, because the following ventricular complex shows no ectopic origin.

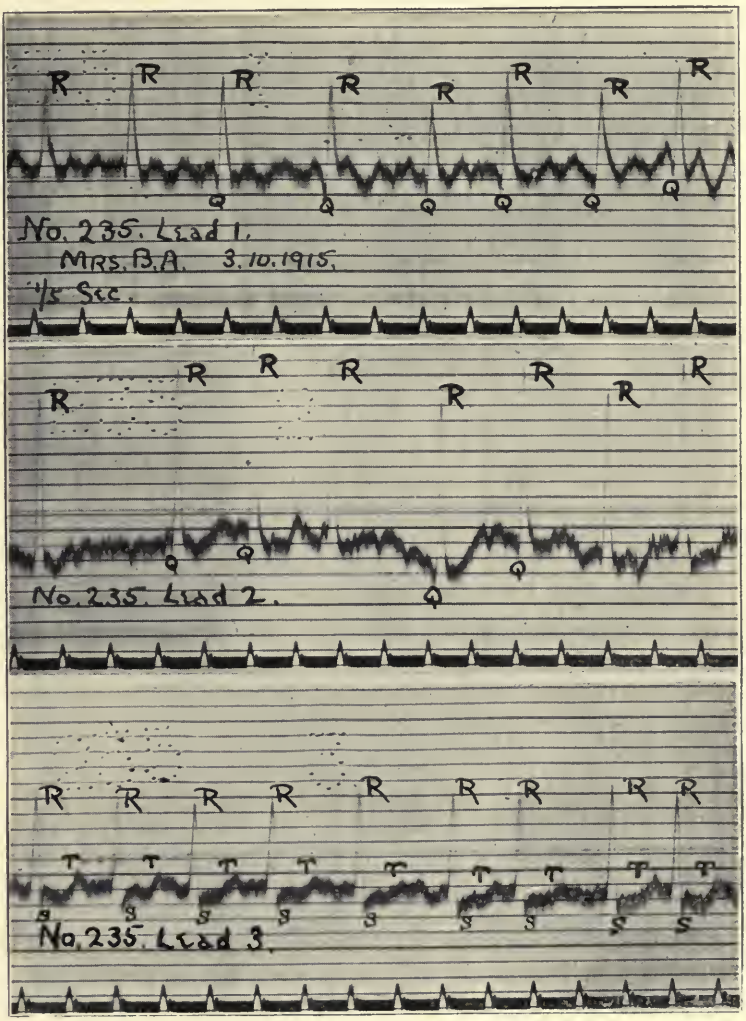

Fig. 7 (Case 2).—Electrocardiogram of same patient as in Figure 4, taken March 10, showing another period of transient auricular fibrillation.

After one week's improvement, the patient awoke one morning from a terrifying dream, and felt her heart pounding violently. Auscultation disclosed a total arrhythmia, with disappearance of all murmurs, a cardiac rate of 130, and a pulse deficit of 50. The systolic pressure was found to have risen to 155, the diastolic remaining at 70. An electrocardiogram (Fig. 7) showed that

coarse fibrillation had again supervened. In Lead I, especially, the fibrillatory waves were so marked and regular that at first the condition of auricular flutter was suggested. This was rejected, however, as the rhythm of the waves of fibrillation was not absolutely regular and the ventricular response was totally irregular, and not explainable by any combination of heart block. During the same afternoon, the patient suddenly announced that the trouble had stopped, and the rate was found to be much slower (80 per minute) and less irregular. Occasional extrasystoles, however, persisted for forty-eight hours. After one week of normal heart action, the patient was returned to the surgical wards for myomectomy and from this time on she flatly refused to allow further cardiac examination.

It is of interest that the patient later volunteered the information that she had had a strong psychic disturbance before each cardiac attack. It is of course possible for a third and unknown factor to have been responsible for both the nightmare and the paroxysmal attack of fibrillation, but the presumption is strong that the cardiac attack was induced by nervous excitement. The chronic endocarditis, enlarged heart and positive Wassermann would all indicate a basic myocardial involvement requiring only the nervous excitation to produce the paroxysm of fibrillation. The appearance of auricular extrasystoles for a few days after each attack is also of interest. It is impossible to say whether these also were of nervous origin or a sign of myocardial degeneration, but here again the time of their appearance affords a strong presumption that the psychic element was at least one factor in their production. A recent report, one year after the period of observation, states that the patient is now in a state of chronic decompensation and that the arrhythmia has become permanent.

Summary of Case.—In a highly excitable, nervous woman, on several occasions strong emotional excitement was observed to be followed by transient attacks of auricular fibrillation. Though the blood pressure was higher during the periods of fibrillation, the state of the pressure just preceding the attacks could not be determined. After the normal auricular activity had returned, the regular rhythm was disturbed for one or two days by occasional auricular extrasystoles. After repeated attacks during the next year, the fibrillation, which had a probable syphilitic myocarditis as a basis, became permanent.

III. TRANSIENT AURICULAR FIBRILLATION OF TOXIC ORIGIN

Case 3.—W. W., a white man, single, aged 40 years, was referred to me for examination on Oct. 12, 1915, by Dr. Newlin, on account of extreme palpitation, dyspnea and arrhythmia of two days' duration. One brother had died of heart disease, following over-indulgence in alcohol, and there was a general family tendency toward overeating and overdrinking. Except for occasional attacks of tonsillitis, the patient had not had any severe infections, but had always eaten too much, and had been a steady consumer of alcohol, but seldom to the point of intoxication. For years he had had some distress after eating and had occasional attacks of heartburn. He had always considered himself in excellent health, however, had not overworked, and had been able to undertake violent exercise without the slightest embarrassment.

The present illness began two months previously while the patient was on a hunting trip in the Rocky Mountains (altitude 5,000 feet). Following an attack of acute bronchitis, the patient noticed that he easily became dyspneic and tired, and that his heart occasionally "skipped" beats. The trip was abandoned, and with appropriate treatment the symptoms disappeared. Systolic blood pressure at this time was 150. In three weeks' time the patient felt

entirely well, except for a mild afebrile tonsillitis, which persisted for several weeks. On a carbohydrate-poor diet he succeeded in losing 50 pounds and the systolic blood pressure dropped to 140. He then began three days of increased alcohol consumption, and became nervous and irritable for several days, but without cardiac symptoms. Then without adequate explanation, after one week of total abstinence, extreme palpitation and arrhythmia developed, with dizziness on standing. The systolic pressure at this time was only 110, diastolic 90. This attack had continued for the two days immediately preceding his visit to the hospital, but he had improved sufficiently to walk without distress.

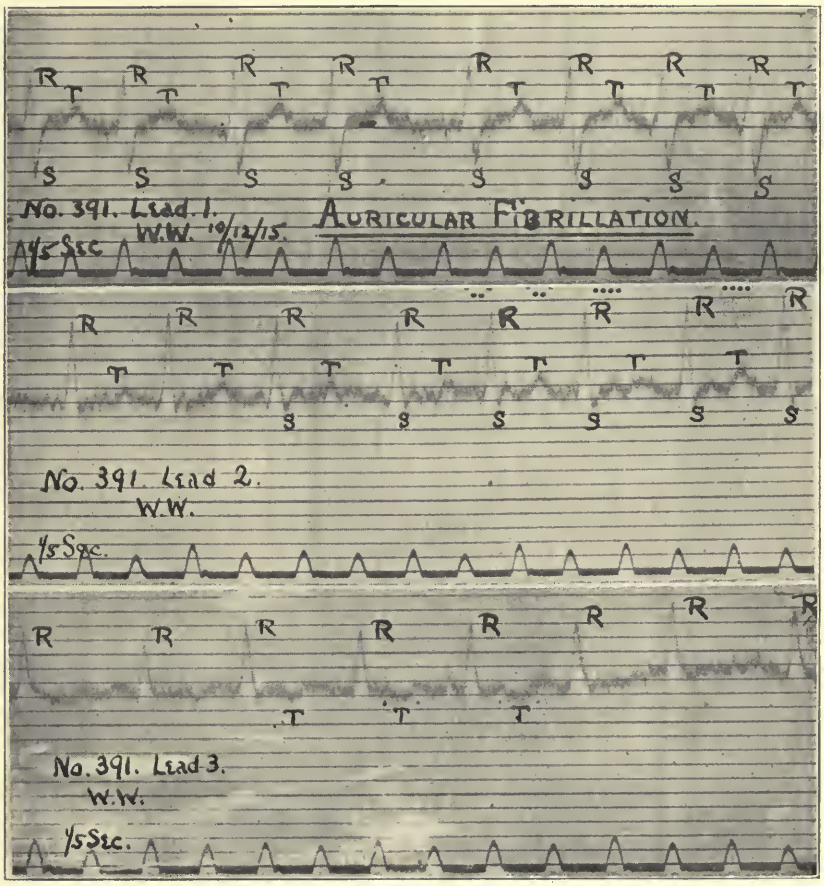

Fig. 8 (Case 3).—Electrocardiogram of patient W. W., who had no discoverable organic lesion, showing transient auricular fibrillation of toxic origin

Physical Examination.—The patient was a large, powerful, well-nourished man, weighing 258 pounds. Although normally rather lethargic, he was at that time apprehensive and slightly dyspneic. The eyes were negative. The tongue was moderately coated, the tonsils red and swollen, but without exudate. There were irregular heavings of the neck, but no distinct venous pulsation. The pulse rate was about 120 and very irregular in force and rhythm. The vessel wall was indefinitely palpable. The heart rate by auscultation was 160, also irregular in force and rhythm, giving a pulse deficit of 25 per cent. The

apex beat was not visible or palpable; the cardiac dulness extended to the right border of the sternum in the fourth space, and 1 cm. to the left of the midclavicular line at the fifth space. No murmurs were audible, but the muscle sounds were rumbling and of poor quality. Examination of the lungs and abdomen was negative. The legs showed very slight pitting on sustained pressure. Frequent urine examinations were always negative.

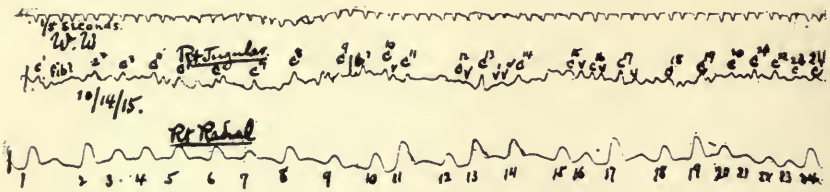

Fig. 9 (Case 3).—The polygram taken immediately after the electrocardiogram shown in Figure 8 exhibits in a more marked degree the irregularities of force and rhythm. The unmarked "c" waves of the jugular pulse indicate the amount of pulse deficit.

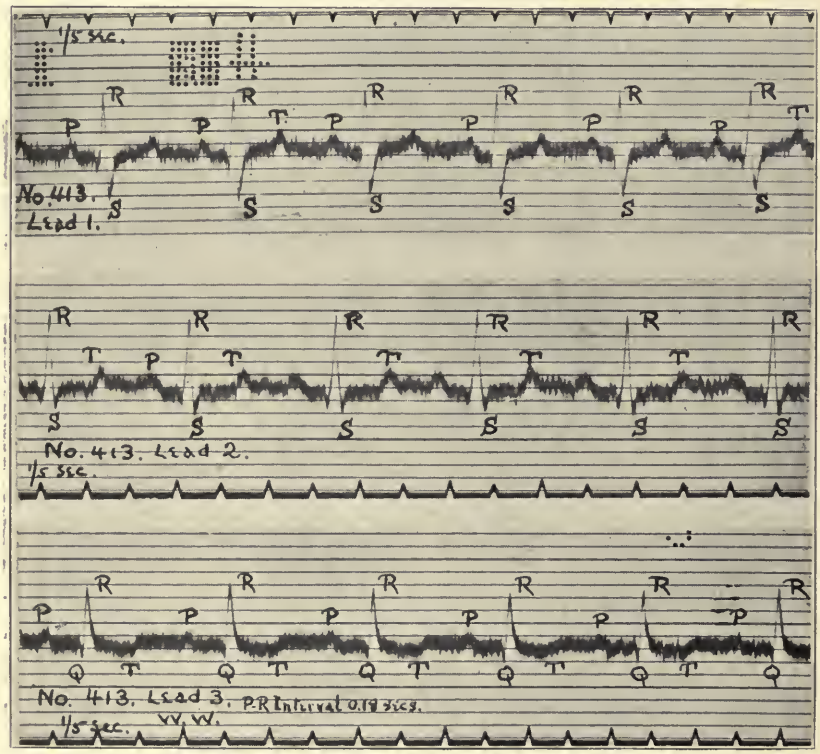

Fig. 10 (Case 3).—Electrocardiogram of same patient as in Figure 8, taken three weeks later, showing normal rhythm.

After three days' treatment, consisting of digipuratum (0.1 gm. four times a day) and local applications to the tonsils, the patient's condition was greatly improved, with cessation of palpitation, dyspnea and cardiac distress. This

was confirmed by Dr. Newlin, who found the heart action and sounds normal and no pulse deficit. The systolic blood pressure was 120 and the diastolic 80. As a result of this improvement the patient resumed his former habits of overeating and overdrinking and in seven months had another cardiac attack lasting three days, which again responded to digitalis. This attack occurred in the middle of the night, while the patient was trying to induce vomiting for the relief of an attack of heartburn. At the present time (May, 1916) he has headaches, gets tired easily, and does not feel so well as before the first attack.

An electrocardiogram (Fig. 8) taken on the patient's first visit showed a distinct arrhythmia with absence of the P wave and with the coarse type of auricular fibrillation. The delirium cordis, however, was much more strikingly shown in the polygraph (Fig 9) taken at the same time, although by this time the patient felt much better and could not say whether or not his heart action was irregular. An electrocardiogram (Fig. 10) taken three weeks later showed a normal regular rhythm with well-developed P wave. The form of the ventricular complex is but little changed from that of the former record.

Summary of Case.—In an adult man, without previous signs of cardiac disease, but with a history of heartburn and chronic overindulgence in food and alcohol, signs of slight cardiac decompensation developed three months before observation. After a short period of improved health, auricular fibrillation with marked cardiac symptoms developed without apparent adequate cause. This persisted for three days, but disappeared under appropriate treatment of rest, digitalis, and local treatment of a subacute tonsillitis, and up to the present time (eight months) has not reappeared, except for one other transient attack lasting for three days. An underlying myocardial weakness is probably in this, as in the other cases discussed in this series, an important factor. While it is impossible absolutely to identify the determining cause of the attack of fibrillation, the blame most probably must fall on either alcohol or the subacute tonsillitis. There were very few signs of decompensation at any time and with the removal of the sources of intoxication, the fibrillation ceased; and yet on account of the probable myocardial disease, a recurrence with correspondingly grave prognosis, must be considered as probable.

IV. TRANSIENT AURICULAR FIBRILLATION DURING DECOMPENSATION IN PANCARDITIS

Case 4.—J. P., a white man, single, 18 years old, was admitted to the hospital Feb. 16, 1916, during an attack of severe decompensation, superimposed on chronic valvular disease, cardiac hypertrophy and chronic nephritis. The chief complaints were dyspnea, cough, edema of buttocks and extremities. Although cardiac symptoms had been present only four years and then occurred without determined adequate cause, it is probable that the cardiac disease started during a severe undiagnosed illness in infancy, which lasted eighteen months. He also was said to have had measles three times during childhood, but his past history and family history is otherwise negative. Although he had had two or more attacks of decompensation before this, he was "passed" by a railroad physician two and one-half years before. The patient presented the usual signs of a decompensated heart disease of long standing, with flushed face, bulging precordium, distended veins, tender liver, ascites and right-side hydrothorax. His heart was enlarged both to the right and to the left and

a loud double mitral murmur was audible with an accentuated second pulmonic sound. The systolic blood pressure varied between 110 and 132; the diastolic between 93 and 110. The venous blood pressure equaled 14 cm. (water). The urine has always contained a large amount of albumin and

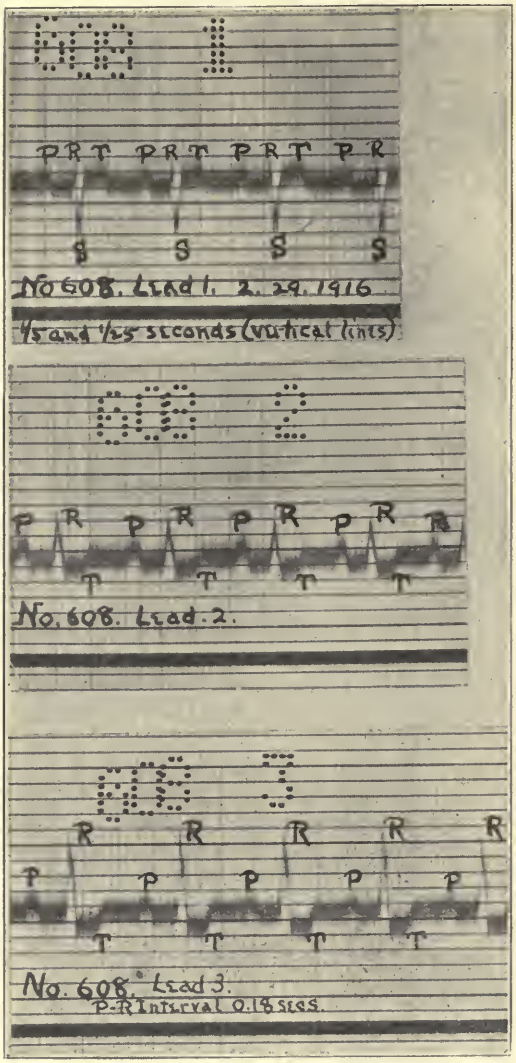

Fig. 11 (Case 4).—Electrocardiogram of patient J. P., a case of fatal mitral stenosis with decompensation, taken Feb. 29, 1916, showing normal rhythm, with right ventricular preponderance.

occasional hyaline casts. The phenolsulphonephthalein elimination was 40 per cent. The blood counts were normal. The Wassermann reaction was negative. An orthodiagram showed increase of cardiac shadow both to the right and left.

An electrocardiogram (Fig. 11) taken the day after admission showed a regular rhythm with well-defined P wave, and the evidences of preponderating hypertrophy of the right ventricle; the P-R interval was 0.18 second. In spite of absolute rest in bed, digitalis and codein medication, the patient's

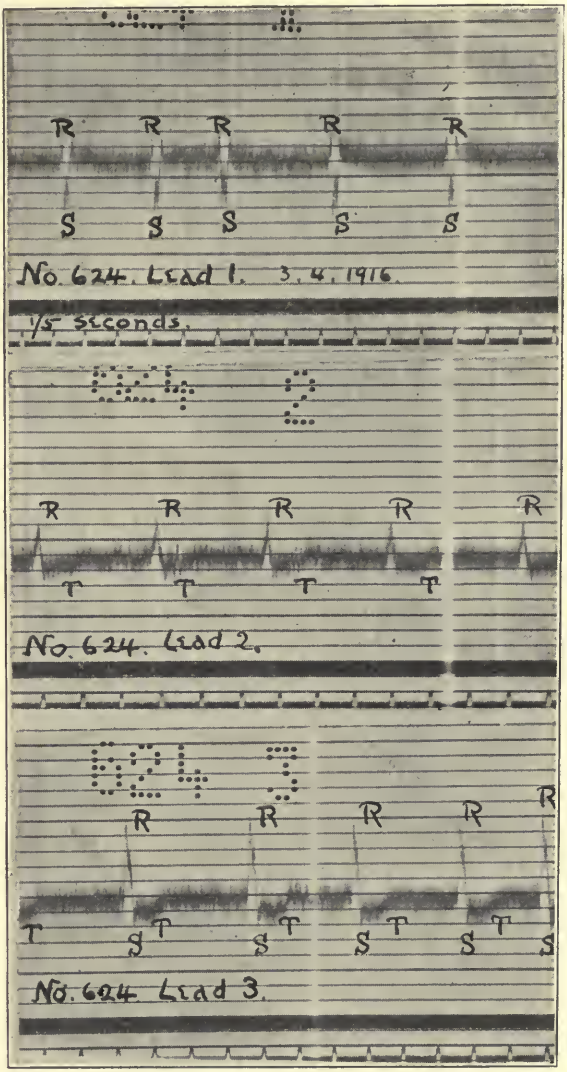

Fig. 12 (Case 4).—Electrocardiogram taken March 4, 1916, of same patient as in Figure 11, showing transient auricular fibrillation. Though the fibrillation has not been of long duration, the waves of fibrillation are not visible.

condition became steadily worse, with increased edema, insomnia, nausea and vomiting. An electrocardiogram (Fig. 12) taken twelve days later failed to show any change, and did not show any of Cohn's digitalis effects. A third record (Fig. 13), taken four days later, revealed the presence of auricular fibrillation,

although no arrhythmia was suspected until the prints of this record became available for study. Another record was taken three days later and it was found that the rhythm had again become regular with reappearance of the P wave. The day before this record was made (that is, two days after recording auricular fibrillation) the signs of acute pericarditis (loud to and fro fric-

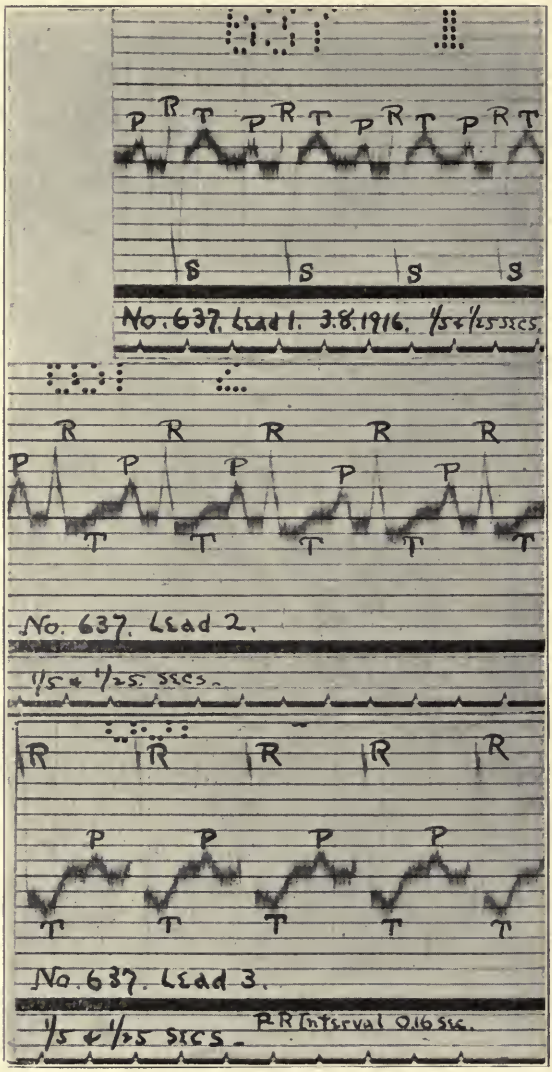

Fig. 13 (Case 4).—Electrocardiogram taken March 8, 1916, of same patient as in Figure 11, showing normal rhythm again, with large P Wave.

tion rub) became manifest, with increase in pulse rate (110 to 140), development of fever, and general aggravation of symptoms. Although these signs were definitely not present in an examination made the day fibrillation was determined, nevertheless an infection, not sufficiently advanced to cause signs,

cannot be ruled out as the added insult that provoked the auricular fibrillation. From this time on the patient became steadily worse, dying in four days from heart failure.

At necropsy the following conditions were found: Concentric hypertrophy of the right ventricle (weight 270 gm.); concentric atrophy of the left ventricle (weight 70 gm.); hypertrophy and dilatation of the right auricle, and concentric hypertrophy and chronic mural endocarditis of the left auricle; chronic mitral endocarditis (extreme stenosis and thickening, with sclerosis of chordae tendineae and tips of papillary muscles); acute fibrinous pericarditis, and (slight) acute vegetation mitral and mural endocarditis; chronic fibrous pleurisy and pericarditis (basal); general chronic passive congestion of viscera; hydrothorax (bilateral) and ascites. Histologic examination confirmed these findings and showed surprisingly little myocardial fibrosis.

Summary of Case.—A boy of 18, suffering with mitral stenosis, was admitted to the hospital in an extreme stage of decompensation, but with normal cardiac rhythm. His condition became steadily worse and eventually auricular fibrillation developed, and the next day an acute pericarditis was found to be present. Fibrillation was replaced after three days by normal rhythm, but death occurred four days later from cardiac failure with persistence of the acute pericarditis. At autopsy an extreme mitral stenosis, with cardiac hypertrophy and dilatation was found.

V. DEVELOPMENT OF PERMANENT AURICULAR FIBRILLATION

In two cases the onset of auricular fibrillation occurred while the patient was under observation. Although the first attack in each of these cases proved to be permanent, they are included in this series on account of certain prognostic indications that they offer.

Case 5.—L. Z., a Polish woman, 33 years old, married, was admitted to the maternity ward of the University Hospital, Jan. 6, 1915, in her fourth pregnancy. The first three pregnancies were normal, but after the birth of the third child, she had a severe attack of "grippe," was in bed after that for three months, and was told by her doctor at that time that she had heart trouble. She had had scarlet fever, measles, chickenpox and typhoid as a child, but had never had sore throat, acute rheumatic fever, or any symptoms of heart disease. Her social and family histories were negative.

Her present attack of decompensation began about the seventh month and gradually grew worse as pregnancy progressed, until in the ninth month labor was induced by Dr. Hirst on account of extreme dyspnea and edema. After delivery her symptoms were much improved, but one week later an attack of intense dyspnea ensued, with precordial pain and a dry, nonproductive cough. She also suffered from anorexia, constipation, headache, weakness, and pain in both breasts (baby had been weaned two days before).

Physical Examination.—When transferred to the medical ward, the usual signs of marked decompensation were found. The pulse was regular, rapid, quick, fair volume and tension and the wall of the artery not sclerosed. The systolic blood pressure was 130, the diastolic 80. There were forcible arterial pulsations in the neck, with apparently the ventricular type of venous pulse. The cardiac impulse was forcible, 17 cm. from the midline (following curve of chest), almost in midaxilla, in the fifth interspace. The cardiac dulness extended 5 cm. to the right of the midline, 17 cm. to the left. At the apex the first sound was loud and preceded by a presystolic murmur and thrill, a systolic

murmur also being heard nearer the sternum. The second pulmonic was accentuated, the liver enlarged and palpable and râles audible at the bases of the lungs. There was generalized edema, ascites and bilateral hydrothorax. The blood showed a moderate anemia. The specific gravity of the urine was 1.028, and it contained a cloud of albumin, and hyaline, granular and leukocytic casts. The phenolsulphonephthalein elimination was 47 per cent. The Was-



Fig. 14 (Case 5).—Electrocardiogram of patient L. Z., a case of fatal mitral stenosis with decompensation, taken Jan. 8, 1916, showing normal rhythm with right ventricular preponderance.

sermann reaction was negative. An electrocardiogram (Fig. 14) showed a regular rhythm with preponderance of the right ventricle and poorly defined T waves.

Course.—The patient improved slightly under digitalis and hypnotics, but four days after admission she had another attack of dyspnea and tachycardia. The pulse at the wrist was uncountable, the heart rate by auscultation was 196 and apparently regular. The following day, after a good night's rest, the

patient seemed much better and the pulse rate was lower. The day after this, arrhythmia was first noted, and the electrocardiograph (Fig. 15) established the diagnosis of auricular fibrillation. Although there is no record of the heart rhythm on the intervening day, it is probable that the rapid period was due to auricular flutter, which progressed to fibrillation. The course of the physical signs and several electrocardiograms taken in the next few days

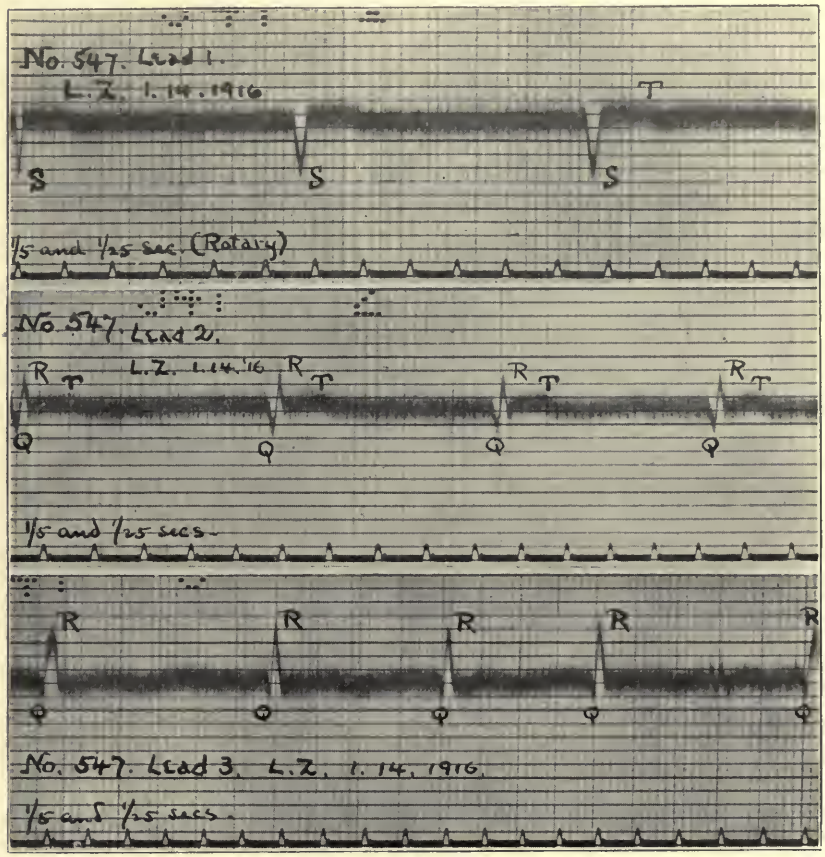

Fig. 15 (Case 5).—Electrocardiogram of same patient as in Figure 14, taken January 14, showing permanent auricular fibrillation. Though this symptom has not been of long duration, the waves of fibrillation are not visible.

confirmed the diagnosis of fibrillation and recorded the response of the heart to digitalis (slowing of rate, lessening of arrhythmia, change in form and Q and T waves). At no time were the waves of fibrillation of the coarse type. The patient, however, failed to improve clinically, and succumbed in three days with the signs of acute dilatation. Necropsy was refused.

Summary of Case.—A woman with mitral stenosis of at least four years' duration had such severe signs of decompensation during her fourth pregnancy that labor had to be induced. She improved during the first week of the puerperium, but then a second and more severe

stage of decompensation set in. In the third day of this attack a very rapid pulse rate was initiated (auricular flutter?) and this progressed to auricular fibrillation, which persisted until death three days later.

The development of auricular fibrillation after a transient period of flutter has been frequently observed; in fact the administration of large doses of digitalis has been recommended in cases of auricular flutter in the hope that the disturbance may pass on to fibrillation and thence, perhaps, return to normal rhythm. The contingency must at least be considered, therefore, in the present case that digitalis was a contributing factor to the causation of fibrillation.

VI. DEVELOPMENT OF PERMANENT AURICULAR FIBRILLATION DURING CARDIAC DECOMPENSATION

Another case is reported in which auricular fibrillation developed after three years occasional observation.

CASE 6.—M. H., an American woman, 35 years old, married, was admitted to the University Hospital on March 21, 1916, with the usual signs and symptoms of cardiac decompensation. This was a recurrence similar to those seen in her previous admissions in the spring of 1913 and the autumn of 1914. She had had measles, mumps, scarlet fever and acute articular rheumatism. Her cardiac symptoms were first noted at the time of a second attack of acute polyarthritis thirteen years before, and reappeared during an attack of "grippe" nine years before. For the past four years she has suffered from some shortness of breath and puffiness of the ankles, which on the two occasions mentioned became bad enough to make her seek the hospital. At both these times she improved quickly under hospital care, and she had never noticed any irregularities of her heart further than an occasional dropped beat.

The present illness started two weeks before admission with greatly increased dyspnea, palpitation and pericardial pain. Four days later the patient suffered a "stroke," losing the power of speech and of moving the left arm, but not becoming unconscious. Speech returned after sleep, but the left thumb, index finger and left side of the face have remained numb and weak. Four days after that, sudden pain developed low in the right chest with cough and hemoptysis, and the lesion was later shown by the Roentgen ray to be a pulmonary infarct. Social and family history irrelevant.

Physical Examination.—It was found on examination that the patient was more emaciated than on previous admissions; the tongue was dry and coated, with herpes on the lips. The cardiac dulness extended 3 cm. to the right of the midline and 13 cm. to the left. The apex beat was well localized in the fifth space 2 cm. outside of the midclavicular line. There was a harsh systolic murmur, best heard at the apex and transmitted to the base and axilla. No arrhythmia was noted. The liver was palpable 4 cm. below the costal margin and the right kidney was also palpable. There was dulness and râles at the bases of both lungs, but more marked on the right. The leukocytes varied between 10,000 and 14,000; hemoglobin 95 per cent., red blood cells 5,480,000. The urine was acid, specific gravity 1.018, contained a cloud of albumin, urates, but no casts. The Wassermann reaction was negative. The systolic blood pressure varied between 115 and 120, the diastolic between 77 and 90. The signs of decompensation decreased steadily during the patient's stay in the hospital, so that she was able to leave in one month in very good condition. The cardiac arrhythmia, which was first discovered by electrocardiographic examination, was still present, but frequently had been so slight that it could not be detected by simple digital examination of the pulse.



Fig. 16 (Case 6).—Electrocardiogram of patient M. H., a case of mitral stenosis with decompensation, taken April 14, 1913, showing normal rhythm (sinus arrhythmia).



Fig. 17 (Case 6).—Electrocardiogram of same patient as in Figure 16, taken in November, 1914. The figure shows occasional auricular premature contractions.

Electrocardiograms (Fig. 16) were taken during each stay at the hospital. The one taken in 1913 showed a normal rhythm and complexes, with a P-R interval of 0.18 second. No abnormalities of rhythm were noted either during the examination or during the patient's stay in the hospital. The electrocardiogram (Fig. 17) taken in 1914 showed, besides some small changes in the form of the ventricular complex, the same P-R interval as on the first admission, but two definite auricular extrasystoles in addition. The large P wave

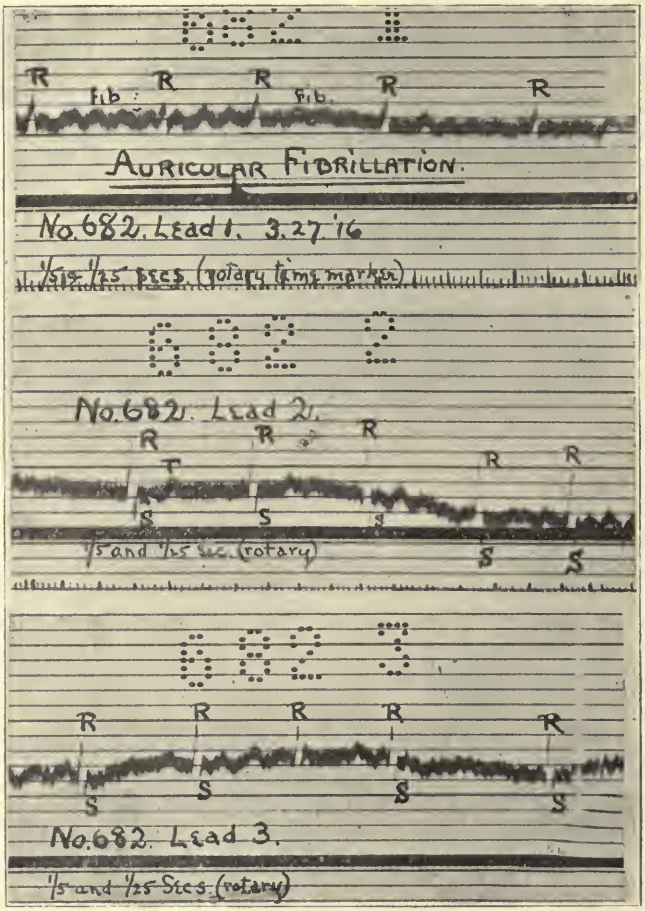

Fig. 18 (Case 6).—Electrocardiogram of same patient as in Figure 16. showing permanent auricular fibrillation (waves of coarse type).

characteristic of mitral stenosis persisted. On the patient's last admission in March, 1916, electrocardiograms (Fig. 18) taken on several occasions constantly showed a coarse type of auricular fibrillation. The form of the ventricular complexes, however, had changed very little from that of the two former admissions. Although the patient improved steadily from a clinical point of view, fibrillation persisted with a gradual decrease of the coarseness of the fibrillation waves.

Summary of Case.—In a case of mitral stenosis of some years' standing with recurrent periods of decompensation, electrocardiographic records were made over a period of three years. At first the rhythm was normal, next was broken by occasional auricular extrasystoles and finally was found to have been replaced by a constant, coarse type of fibrillation. If the history may be relied upon, this probably developed within two weeks of admission to the hospital, when decompensation was further complicated by cerebral and pulmonary emboli and infarct formation.

GENERAL COMMENT

A comparison of the foregoing cases with those mentioned in the literature allows the change from normal rhythm to auricular fibrillation to be subdivided into three types.

In the first group falls the first case of this series, twelve of Cohn's[11] pneumonia cases, all four of those reported by Fahrenkamp, Robinson's[12] recent case, the fourth of Heitz's and the sixth of Fox's series. In these cases the predominant factor was some acute infection or intoxication (pneumonia, septicemia, hyperthyroidism), and the attack of fibrillation was single. No organic cardiac lesion was found or need be presumed, and when the infection or intoxication was removed the rhythm returned permanently to normal.

In the second group, and this comprises the larger number of those cases reported as paroxysmal auricular fibrillation, belong the second and probably the third cases of this report, also the remaining nine of Heitz's, the four of Hornung's, four of Fox's series, and the single cases of Robinson, Popper, and Lewis and Schleiter. At the time of observation all but three of these patients were in the sixth or seventh decade of life, but the onset of attacks when mentioned occurred as follows: Two in the third decade, two in the fourth, five in the fifth, five in the sixth, and six in the seventh decade. The average duration of the condition was over nine years. Both sexes were equally involved. Previous diseases bore no relationship to the condition; even the cardiac condition varied greatly. In eight cases mitral lesions were present, but in ten others no valvular lesion was found. In nearly all, however, there was distinct evidence of myocardial disease. The blood pressure was found increased in seven and not increased in eight. Arteriosclerosis was noted in ten. Factors determining the paroxysms were either absent or widely varying in character. In six, emotional excitement preceded attacks and in two others they were attributed to a general increase in

11. Cohn, A. E.: Certain Phases of the Action of Digitalis in Pneumonia, Meeting of Am. Soc. for the Advancement of Clin. Investigations, Washington, D. C., May 8, 1916, unpublished.

12. Robinson, G. C.: Transient Auricular Fibrillation in a Healthy Man Following Hydrogen Sulphid Poisoning, Jour. Am. Med. Assn., 1916, lxvi, 1611.

the patient's nervousness. In four, attacks were induced by exercise or fatigue, but in three others they nearly always occurred during sleep. Overeating (three cases), defecation, and asthmatic attacks were held responsible in other cases. Many of these factors might be grouped under the head of conditions that raise blood pressure, but in some cases this factor was definitely absent. The duration of the individual attacks was also extremely variable, ranging from a few minutes to several weeks; in most cases, however, they lasted a few hours. In the early stages the attacks tended to be either short or infrequent, the duration and frequency of the attacks increasing as the disease progressed. They usually began abruptly, without premonitory symptoms, and caused more or less severe cardiac embarrassment. The attacks ended either during sleep or with such abruptness that the patient could notice the return to regular rhythm. In only one case were extrasystoles noticed between attacks, and in two cases there occurred also attacks of paroxysmal tachycardia. In this connection Lewis and Schleiter have called attention to the closely related mechanism of auricular extrasystoles, fibrillation and paroxysmal tachychardia. Six patients died while under observation (mostly from cardiac complications during regular rhythm); in five others fibrillation had become permanent; while six of the remaining ten were considered as improved. Venesection, digitalis and quinin have been used successfully and the ordinary treatment of cardiac failure seems advisable.

In a third group, represented by the last three cases of this report and the fourth of Fox's series, the onset of fibrillation should be regarded as but one more link in the chain of cardiac failure. In all these cases the signs of mitral disease with decompensation were prominent and had existed for years. In two cases the first attack of fibrillation proved to be permanent, one of these being preceded by auricular extrasystoles, in one other the permanent period was preceded by one transient period, and in the fourth a transient period lasting three days occurred a few days before death from cardiac failure (normal rhythm). The development of most of the cases of permanent auricular fibrillation is probably of this character, but closer observation and wider use of graphic methods would probably reveal one or more previous transient periods. As auricular fibrillation aggravates the prognosis, energetic treatment should be instituted at these times, in order to delay or avoid the onset of the permanent condition. That this should not include too large doses of digitalis is indicated by the fact that in two cases at least (Case 3 of this report and Robinson's case) digitalis was considered as a possible factor in the production of fibrillation. Its value as a cardiac remedy, however, especially after fibrillation is established, makes it a necessary aid in practically all such cases.

CALIFORNIA

SUMMARY

Four cases are described in which the transition of the cardiac mechanism was observed from normal rhythm to auricular fibrillation and back again. In two others the development of permanent auricular fibrillation was observed. These have been compared with similar cases in the literature.

CONCLUSIONS

Transient auricular fibrillation is a comparatively rare condition, although the more widespread and frequently repeated use of the string galvanometer will probably reveal many more cases than are now available for study.

The change from normal rhythm to auricular fibrillation occurs in three well-defined groups:

1. In the course of an acute infection, such as pneumonia or septicemia, or of an acute intoxication, such as alcohol or hyperthyroidism, or possibly from other temporary causes, one or more attacks of fibrillation may occur for several days, but disappear permanently when the source of intoxication is removed. In this group permanent myocardial damage is probably not present.

2. In another group, probably always associated with underlying myocardial degeneration, paroxysms lasting from a few minutes to many hours or even days, may be induced by a great variety of causes and occur over a period of many years. They tend, however, to become more lasting or more frequent or both, and eventually with the progress of the myocardial disease the fibrillation becomes permanent. Death may occur, however, before permanent fibrillation has ensued, or clinical improvement may take place with the onset of fibrillation. The term "paroxysmal" is most aptly applied to cases of this group.

3. In a third group, in which the signs of valvular or myocardial disease are more prominent, the original change from normal rhythm to fibrillation is liable to be permanent, or at least be preceded by only a few transient periods. A determining factor in such cases is liable to be some cardiac complication, such as pulmonary embolus, acute pericarditis, or the added strain of pregnancy, and may be preceded by a transient period of flutter.

No relationship between the onset of fibrillation and changes in blood pressure could be established.

In the earlier stages of fibrillation the electrocardiogram usually shows coarser waves of fibrillation, so that this evidence, when present, may be guardedly used to influence favorably the prognosis.

The occurrence of fibrillation, while a bad factor in prognosis, does not necessarily indicate either permanency or a fatal outcome. It is of graver significance when it occurs in valvular cases with prominent signs of decompensation, and of least significance in the cases of the first group.

The usual treatment of heart failure (rest in bed, the digitalis group, removal of sources of intoxication, etc.) help to terminate attacks of fibrillation, but excessive doses of digitalis may help to induce this condition.

These cases were studied in the wards and laboratory of the University Hospital, while under the care of Drs. Stengel, Hirst, Anspach and Newlin, to whom my thanks are due.

UNIVERSITY OF CALIFORNIA LIBRARY,
BERKELEY

THIS BOOK IS DUE ON THE LAST DATE
STAMPED BELOW

Books not returned on time are subject to a fine of 50c per volume after the third day overdue, increasing to $1.00 per volume after the sixth day. Books not in demand may be renewed if application is made before expiration of loan period.

MAR 4 1932

MAY 14 1951

MAY 14 1951

75m-7,'30

Makers
Syracuse, N. Y.
PAT. JAN. 21, 1908

UNIVERSITY OF CALIFORNIA LIBRARY